Seizure 18 (2009) 396–399

Contents lists available at ScienceDirect

Seizure

journal homepage: www.elsevier.com/locate/yseiz

Retinal ganglion cell toxicity due to oxcarbazepine and valproic acid treatment in rat

Zeynep Aktaş [a,*], Ali Cansu [b], Deniz Erdoğan [c], Gülnur Take [c], Guleser Goktas [c], Sengul Ozdek [a], Ayse Serdaroglu [d]

[a] Gazi University School of Medicine, Department of Ophthalmology, Turkey
[b] Karadeniz Teknik University School of Medicine, Department of Pediatric Neurology, Turkey
[c] Gazi University School of Medicine, Department of Histology and Embryology, Turkey
[d] Gazi University School of Medicine, Department of Pediatric Neurology, Turkey

ARTICLE INFO

Article history:
Received 29 September 2008
Received in revised form 28 January 2009
Accepted 20 February 2009

Keywords:
Oxcarbazepine
Valproic acid
Retinal ganglion cell

ABSTRACT

Purpose: To evaluate and to compare the possible toxic effects of oxcarbazepine (OXC) and valproic acid (VPA) on retinal ganglion cells (RGCs) in rat.
Methods: Forty female Wistar rats (21–24 days old and weighted between 44.6 and 57.3 g) were divided equally into 4 experimental groups which were applied tap water (group 1), 300 mg/(kg day) VPA (group 2), 100 mg/(kg day) OXC (group 3), and both VPA and OXC (group 4) via gavage for 90 days. Enucleation was performed for histopathologic analysis. RGCs were counted under the light microscopic examination.
Results: RGC numbers in OXC and combined OXC-VPA groups were found to be lower than those of control group. On the other hand RGC number was comparable with those of control group in VPA group.
Conclusion: OXC seems to be toxic to RGCs at 100 mg/kg dose when it is been given as a monotherapy or combined with VPA. Single VPA treatment has no effect on RGC number.
© 2009 British Epilepsy Association. Published by Elsevier Ltd. All rights reserved.

1. Introduction

Epilepsia is a neurologic disorder that may be associated with visual alterations. There are various antiepileptic drugs that have been used in the treatment of epilepsia. In patients with epilepsia, visual disturbances may be caused by either the epilepsy itself or by the anticonvulsant therapy which is being used to control seizures. In recent years, visual side-effects have been studied in epileptic patients treated with different antiepileptic drugs. Valproate (VPA) is the one of these drugs that has been widely used for the treatment of epilepsy and other neuropsychiatric diseases such as bipolar disorders, migraine, and generalized mood disorders for nearly 40 years.[1–3] VPA has been demonstrated to cause deficits in color vision after a short treatment period.[4] On the other hand, in other study, retinal nerve fiber layers in patients with epilepsia were also analyzed clinically by using optical coherence tomography (OCT) to find out the mechanisms underlying this color-vision impairment.[5] However, no significant differences were found between study groups.

Oxcarbazepine (OXC) is a newer antiepileptic agent that has been used recently as a monotherapy or add-on treatment for partial seizures, with or without secondarily generalized seizures, and primary generalized tonic–clonic seizures.[6] Its use for childhood epilepsies has been increased recently.[7] OXC has been reported as a relatively safe antiepileptic drug, without significant visual impairment. On the other hand, it has also been demonstrated to cause diplopia and blurred vision in various studies although the underlying mechanism has not been known.[8]

Histopathologic and anatomic changes in the eye secondary to the VPA and OXC treatments have not been reported yet. Visual symptoms secondary to the VPA and OXC therapy may be the sign of optic nerve (ON) or retinal dysfunction. It has been well-known that retinal ganglion cell (RGC) axons compose ON. Furthermore, RGC loss secondary to the some toxic, ischaemic or traumatic insults may cause clinically significant ON dysfunction and color vision impairment. The aim of the current study was to investigate the histopathologic changes in RGC layer induced by direct toxic effects secondary to VPA and OXC treatments.

* Corresponding author at: Barış Sitesi, 59 sokak, No: 7, Eskişehir Yolu – Ankara, Turkey. Tel.: +90 312 284 7192; fax: +90 312 212 5794.
E-mail address: drzeynep2000@yahoo.com (Z. Aktaş).

1059-1311/$ – see front matter © 2009 British Epilepsy Association. Published by Elsevier Ltd. All rights reserved.
doi:10.1016/j.seizure.2009.02.003

2. Materials and methods

2.1. Animals

The 46 female Wistar rats (aged between 21 and 24 days old and weighted between 44.6 and 57.3 g) from Gazi University Medical Faculty Animal Laboratory were used in this experimental study. All animals were housed in plastic cages at a constant room temperature (21–22 °C) and in a 12 h light/12 h dark cycle (lights on at 07:00 am). Rats were given free access to food and water. All animal experiments were carried out in accordance with the European Communities Council Directive of 24 November 1986 (86/609/EEC) and were approved by the Animal Care Committee of Gazi University.

2.2. Experimental procedure and dosing

Rats were divided into 4 experimental groups including 20 eyes of 10 rats in each group. Experimental groups were as follows: group 1 (control group), that was applied control solution, group 2 (VPA group), that was applied 300 mg/(kg day) of VPA (Depakin® 200 mg/1000 μL solution, Sanofi Dogu, Istanbul, Turkey), group 3 (OXC group), that was applied 100 mg/(kg day) of OXC (Trileptal® 60 mg/1000 μL solution, Novartis, Istanbul, Turkey), and group 4 (combined VPA-OXC group), that was applied 300 mg/(kg day) VPA and 100 mg/(kg day) OXC. Ordinary drinking water was used as the control solution. Dosages of drugs in groups 2, 3 and 4 were defined according to the weights of rats. Rats were weighted weekly and drug doses were adjusted accordingly. For example, a 100 g rat in group 4 at fifth week of the treatment received 30 mg VPA according to the dose of 300 mg/(kg day) and 10 mg OXC according to the dose of 100 mg/(kg day). For this purpose, 150 μL of the VPA solution with the concentration of 200 mg/1000 μL and 170 μL of OXC solution with the concentration of 60 mg/1000 μL were applied. Control solution and antiepileptics were administered orally for 90 days with 12 h intervals in two divided doses via gavage prepared specifically by bending its tip of metal tube and coating it with silicon.

VPA dose has been adopted from the study by Roste et al.[9] In the literature, the antiepileptic dose of OXC was proposed as 30 mg/kg for single use and higher for chronic use.[10] Cansu et al.[11] also used the higher dose of 100 mg/(kg day) in their study.

2.3. Histopathologic analysis and RCG count

All tissues were transferred immediately to 10% formal saline for 72 h, dehydrated in graded alcohols and embedded in paraffin wax. 4 μm sections were cut on a microtome (Leica SM 2000, Germany). Afterwards, the slides were counterstained with heamatoxylin-eosine. Images were taken of each section using a Leica DM 4000B (Leica, Weetlar, Germany) photomicroscope and a Leica DFC280 plus camera. The number of the RGCs is measured manually by using Qwin (V3 Plus image) software program in consecutive areas for serial cutaways taken from each subject.[12,13] Morphologic alterations in RGC layer were also evaluated under the light microscopic examination in a masked fashion.

2.4. Statistical analysis

RGC numbers in groups 2, 3 and 4 compared with group 1 (control) by using Mann–Whitney *U* test. SPSS version 11.0 system for personal computer was used and $p < 0.05$ was regarded as statistically significant for all statistical analyses.

3. Theory

Theory of the current study was that VPA and OXC, popular antiepileptic drugs, might have caused direct toxic effects in RGC layer based on the fact that they affect visual function.

4. Results

4.1. RGC count

Mean RGC number in group 1 (control) was 16.4 ± 5.3 (9–28). In group 2 (VPA), RGC number was 14.0 ± 3.1 (10–22) and the difference between groups 1 and 2 was not found to be statistically significant (*p*: 0.128). On the other hand, RGC numbers in group 3 (OXC) and group 4 (combined OXC-VPA) were 12.5 ± 2.7 (8–18) and 10.0 ± 1.9 (6–14). RGC numbers in both groups 3 and 4 were found to be significantly lower than that of group 1 (*p*: 0.012 and *p*: 0.001, respectively).

4.2. Histopathologic examination

In histopathologic examination, there was a classical appearance of RGC layer composed of healthy and homogenous RGCs in group 1 (control; Fig. 1). RGC atrophy with a decrease in thickness of the RGC layer was observed in group 2 (VPA) whereas the anatomy of the RGC layer was relatively to be well-preserved (Fig. 2). In group 3 (OXC), there was a significant anatomic and organizational disruption in RGC layer together with RGC atrophy (Fig. 3). The most prominent histopathologic finding encountered in group 3 was intrastoplasmic edema. Furthermore, the other significant histopathologic finding was nuclear shrinkage of the RGCs. Decreased thickness together with cell loss in RGC layer was also significant in group 3. In group 4 (combined OXC-VPA), there was a significant disruption of RGC layer anatomy together with severe RGC loss and atrophy leading to decreased thickness of RGC layer compared with that of group 1 (Fig. 4).

5. Discussion

In the current study, we investigated the morphologic alterations caused by VPA and OXC treatments, in the RGC layer of rat. We found that OXC treatment caused significant negative effects on the structure and number of the RGCs whereas VPA treatment led only RGC atrophy without causing significant RGC loss.

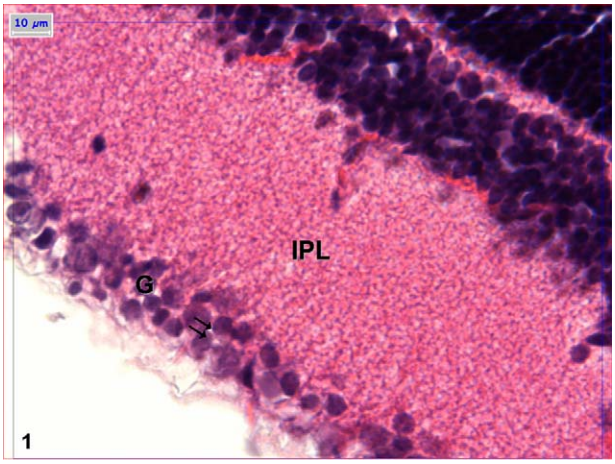

Fig. 1. Light microscopic view of retina in group 1 (control), G: normal RGC layer, IPL: normal inner plexiform layer, ⇉ normal cell nuclei (Heamatoxylin-Eosine, ×400).

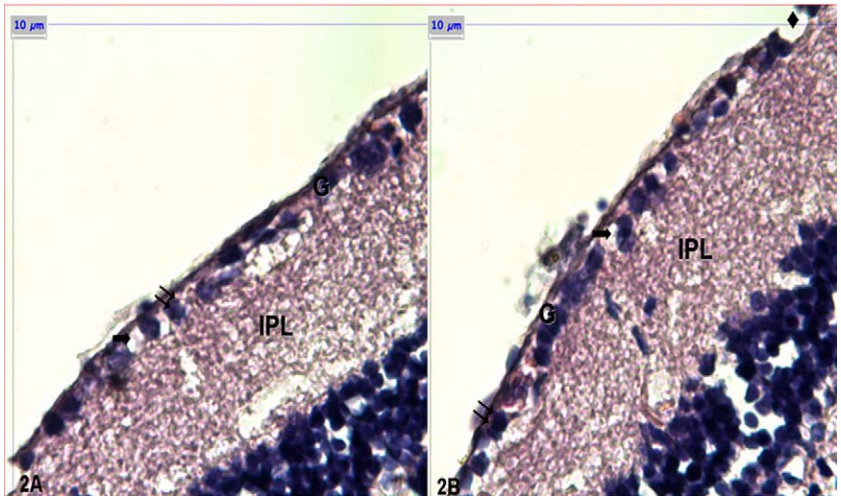

Fig. 2. (A and B) Light microscopic view of retina in group 2 (VPA), G: atrophic RGC layer, IPL: normal inner plexiform layer, →: intracytoplasmic edema, ⇉normal cell nuclei, ◆: separation between cells of RGC layer (Heamatoxylin-Eosine, ×400).

Both VPA and OXC have been used widely for the treatment of epilepsy. VPA is a broad-spectrum antiepileptic drug that has been used as a first-line agent for both the treatment of generalized and partial seizures. Sorri et al.[14] investigated whether initial VPA monotherapy for the treatment of epilepsy causes visual field defects or other visual dysfunction. They found no visual field defect secondary to the VPA treatment but they demonstrated VPA induced abnormalities in color vision. Some other studies in the current literature also support that epilepsy patients treated with VPA monotherapy develop disturbances in color vision even after a short treatment period.[4,15] These effects on color vision might be resulted from changes at the level of the retinal processing or anatomy.

OXC, is a new generation antiepileptic drug and a keto analog of carbamazepine.[16] It has been widely used for the treatment of partial and secondary generalized tonic–clonic seizures with a better tolerability profile. Although it has mainly marketed as an alternative to carbamazepine, there is no reported association between the OXC treatment and wide variety of visual disturbances like carbamazepine.[17] The most common ocular adverse effects associated with OXC are diplopia and blurred vision.[8] It has also been found that OXC caused subtle visual alterations together with saccadic and smooth-pursuit eye movements.[18]

To the best of our knowledge, there is no animal or postmortem study in the literature investigated the underlying changes or mechanisms of these visual disturbances encountered secondary to these agents used for the treatment of epilepsia. There is only one clinical study investigating the relationship between ocular symptoms and retinal anatomy by using OCT.[5] OCT is a useful clinical tool that can measure the thickness of retinal nerve fiber layer and macula. It can be used to support the diagnosis of various ocular diseases affecting the structure of retina and optic nerve such as glaucoma or age related macular degeneration. Structural alterations have been known to precede the development of visual field defects and clinical symptoms in these types of patients. Thus, OCT makes clinician evaluate the correlation between these structural changes and patient's visual symptoms. Lobefalo et al.[5] demonstrated that epilepsy patients did not have any alteration in retinal nerve fiber layer and macular thickness after 1 year of treatment with VPA and CBZ by using OCT and there was no structural alteration even in the presence of color-vision defects. However, in this study, there was no data including RGC layer of these patients since it is not possible to evaluate RGC layer with this device. Color-vision and visual field defects could be a sign of retinal toxicity or optic neuropathies such as glaucoma

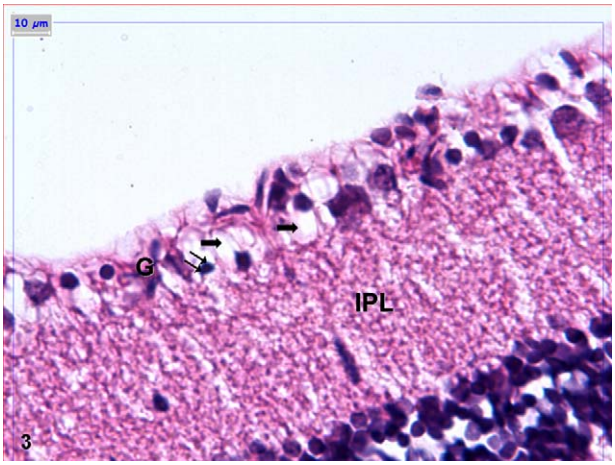

Fig. 3. Light microscopic view of retina in group 3 (OXC), G: degenerated RGC layer, IPL: normal inner plexiform layer →: intracytoplasmic edema, ⇉shrinked nuclei (Heamatoxylin-Eosine, ×400).

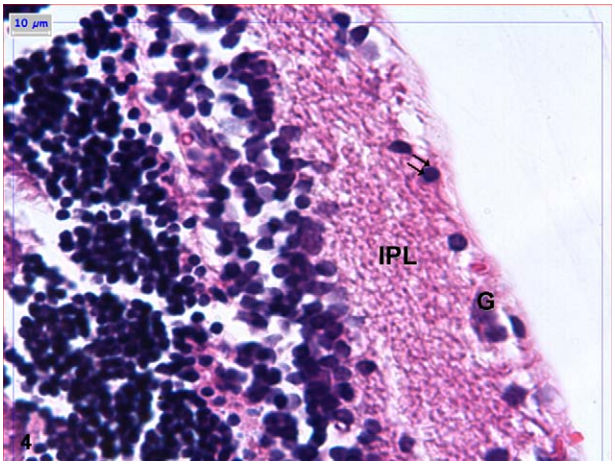

Fig. 4. Light microscopic view of retina in group 4 (combined VPA-OXC), G: RGC layer composed of degenerated and atrophied cells, IPL: inner plexiform layer, ⇉ decreased number of RGC nuclei (Heamatoxylin-Eosine, ×400).

characterized by decreased number of RGCs resulted in decreased macular thickness and optic nerve excavation.[19,20] Macular thickness, retinal layers and changes in optic nerve parameters caused by various ocular diseases are widely evaluated clinically in ophthalmology practice, since these parameters are significantly important for the preservation of visual function. Loss or disruption of RGCs can also affect all of these parameters.

RGCs are also known to be involved in color vision and there are nearly 1 million RGCs in the eye. Information coming from the retina is carried to higher centers through the axons of RGCs. Retina has a complex structure including RGCs that make connections with other cells. Basically, in front of the rods and cones that are located at the back of the retina, there are other types of cells: bipolar cells, horizontal cells and amacrine cells. Retinal processing begins at the output terminal of the cone, cone pedicle and continues through the complex pathways including bipolar cells, horizontal cells amacrine cells and RGCs. The RGCs add and subtract signals coming from many cones.[21] The result of these steps is a signal that is sent to the brain for color vision. So, any insult leading to RGC damage might also cause defective color vision.

Consequently, color vision loss and visual disturbances both may be resulted from chronic RGC loss. It may also be associated with photoreceptor loss as described above. On the other hand, we only investigate the toxic effects on RGCs secondary to OXC and VPA treatments. Loss and disruption of RGCs caused by these antiepileptic drugs may contribute to their side-effects on visual function. However, their effects on photoreceptors may be investigated in further studies.

Color vision and visual field defects might be secondary to the various optic neuropathies. As far as we know, chronic ocular diseases leading to chronic loss of RGCs such as glaucoma or ischaemic retinal diseases can cause further ON damage and secondary visual disturbances. In other words, chronic disruption of RGC layer has been known to be associated with ON dysfunction similar to those seen with glaucoma or ischaemic optic neuropathy. Toxic insults may also affect RGC layer and ON. Histopathologic mechanisms underlying the color vision defects and visual disturbances in these patients have not been known. These possible histopathologic alterations that have not been detected clinically precede the development of clinical symptoms. Duration of the treatment and the dose of the antiepileptic drug may possibly affect the degree of the toxicity or the severity of the clinical symptoms.As a new generation antiepileptic drug, exact place of OXC in the treatment of epilepsia especially in young patients is not clear. Since the fact that it is being relatively free of side effects compared with other antiepileptic drugs, OXC may be thought as a more advantageous treatment option. In this study, we have investigated whether two of the most common antiepileptic drugs, VPA and OXC cause any toxic effects in RGC layer of rat retina. OXC was given with the dose of 100 mg/kg for 90 days that was suggested for its chronic use.[9] We found that OXC caused significant RGC toxicity when it is used in this chonic dose scheme. It caused significant RGC loss and atrophy when it was given as a monotherapy or together with VPA. However, although we used VPA in 300 mg/kg dose, only RGC atrophy was found without significant loss compared with that of OXC treatment.

On the other hand, one of the main drawbacks of our experimental study is the difficulty of the application of these results to human, clinically. The other factor is the doses that was used. Half-life of these drugs may be different in rats compared with those of human. However, it is also difficult to find an acute and chronic doses of antiepileptic drugs exactly in rats compared to human. Thus, the toxic effects that we demonstrated in the current study might also be resulted from the doses that was used.

6. Conclusions

To the best of our knowledge, there has been no knowledge about the histopathologic alterations underlying the ocular side effects of OXC and VPA. Chronic loss of RGCs may lead to serious optic neuropathy causing visual disturbance in long term. However, this should be kept in mind that even OXC, a new generation antiepileptic drug with a fewer ocular side effect profile, might cause a significant toxic RGC loss. Thus, further histopathologic or clinical studies are needed to demonstrate the exact relationship between the RGC loss and OXC or VPA treatments in human. Different doses of OXC and VPA should also be used to find safe, nontoxic and also effective dose in these future clinical studies. The results of our study may provide an important basis for these further studies. Consequently, if they are toxic to RGCs in human, some neuroprotective treatments may be needed to increase RGC survival in patients treated with OXC or VPA therapies.

Acknowledgments

We thank Prof. E. Calguner and all staff of Gazi University Animal Laboratory for their continuous support without any hesitation during our study. We confirm that we have read the Journal's position on issues involved in ethical publication and affirm that this report is consistent with those guidelines.

None of the authors has a financial or proprietary interest in any method or material mentioned.

References

1. Owens MJ, Nemeroff CB. Pharmacology of valproate. *Psychopharmacology Bulletin* 2003;**37**(Suppl 2):17–24.
2. Bowden CL. Valproate. *Bipolar Disorders* 2003;**5**:189–202.
3. Peterson GM, Naunton M. Valproate: a simple chemical with so much to offer. *Journal of Clinical Pharmacy and Therapeutics* 2005;**30**:417–21.
4. Verrotti A, Manco R, Matricardi S, Franzoni E, Chiarelli F. Color vision in epileptic adolescents treated with valproate and carbamazepine. *Seizure* 2004;**13**:411–7.
5. Lobefalo L, Rapinese M, Altobelli E, Di Mascio R, Lattanzi D, Gallenga PE, et al. Retinal nerve fiber layer and macular thickness in adolescents with epilepsy treated with valproate and carbamazepine. *Epilepsia* 2006;**47**:717–9.
6. Glauser TA. Oxcarbazepine in the treatment of epilepsy. *Pharmacotherapy* 2001;**21**:904–19.
7. Bang L, Goa K. Oxcarbazepine: a review of its use in children with epilepsy. *Paediatric Drugs* 2003;**5**:557–73.
8. Kalis MM, Huff NA. Oxcarbazepine, an antiepileptic agent. *Clinical Therapeutics* 2001;**23**:680–700.
9. Sveberg Røste L, Taubøll E, Isojärvi JI, Pakarinen AJ, Huhtaniemi IT, Knip M, et al. Effects of chronic valproate treatment on reproductive endocrine hormones in female and male Wistar rats. *Reproductive Toxicology* 2002;**16**:767–73.
10. Tecoma ES. Oxcarbazepine. *Epilepsia* 1999;**40**(Suppl 5):S37–46.
11. Cansu A, Giray SG, Serdaroglu A, Erdogan D, Coskun ZK, Korucuoglu U, et al. Effects of chronic treatment with valproate and oxcarbazepine on ovarian folliculogenesis in rats. *Epilepsia* 2008;**49**:1192–201.
12. Germain F, Calvo M, de la Villa P. Rabbit retinal ganglion cell survival after optic nerve section and its effect on the inner plexiform layer. *Exp Eye Res* 2004; **78**:95–102.
13. Tunc E, Erdogan D, Gozil R, Bahcelioglu M, Calguner E, Take G, et al. Dose dependant immunohistochemical changes in rat cornea and retina after oral methylphenidate administration. *Anat Histol Embryol* 2008; Nov. 6 [Epub ahead of print].
14. Sorri I, Rissanen E, Mäntyjärvi M, Kälviäinen R. Visual function in epilepsy patients treated with initial valproate monotherapy. *Seizure* 2005;**14**:367–70.
15. Lopez L, Thomson A, Rabinowicz AL. Assesment of colour vision in epileptic patients exposed to single-drug therapy. *European Neurology* 1999;**41**:201–5.
16. Wallace SJ. Newer antiepileptic drugs: advantages and disadvantages. *Brain and Development* 2001;**23**:277–83.
17. Verrotti A, Manco R, Matricardi S, Franzoni E, Chiarelli F. Antiepileptic. Drugs and visual function. *Pediatric Neurology* 2007;**36**:353–60.
18. Zaccara G, Gangemi PF, Messori A, Parigi A, Massi S, Valenza T, et al. Effects of oxcarbazepin on the central nervous system: computerized analysis of saccadic and smooth pursuit eye movements. *Acta Neurologica Scandinavica* 1992;**85**:425–9.
19. Pacheco-Cutillas M, Edgar DF, Sahraie A. Acquired colour vision defects in glaucoma—their detection and clinical significance. *Br J Ophthalmol* 1999;**83**:1396–402.
20. Perason P, Swanson WH, Fellman RL. Chromatic and achromatic defects in patients with progressing glaucoma. *Vision Res* 2001;**41**:1215–27.
21. Neitz M, Green DG, Neitz J. Visual acuity, adaptation and color vision. In: Albert DM, Miller JW, editors. *Albert & Jakobiec's Principles and practice of ophthalmology*. Canada: Saunders Elsevier; 2008. p. 1593–607.