Case Report

Reconstruction of Traumatic External Iliac Artery Dissection Due to Vascular Clamping

Mahir Kırnap,[1] Ümit Özçelik,[2] Aydıncan Akdur,[1] Ebru H. Ayvazoğlu Soy,[1] İclal Işıklar,[3] Feza Yarbuğ Karakayalı,[2] Gökhan Moray,[1] Mehmet Haberal[1]

Abstract

Traumatic external iliac artery dissection after renal transplant is a rare complication, but it should be urgently managed due to its devastating effects on graft and lower limb circulation. External iliac artery dissection is seen more in recipients with diabetes mellitus and comorbid disease. Recipients with external iliac artery dissection should be treated immediately by percutaneus angioplasty or surgical reconstruction. In this study, we reported the management of 2 kidney transplant cases with external iliac artery dissection due to vascular clamping of the artery. External iliac artery dissection was diagnosed by ultrasonography in both cases. After failed percutaneous interventional angioplasty, we reconstructed the external iliac artery dissection surgically and replaced the external iliac artery with polytetrafluoroethylene grafts in both patients. Both patients were discharged with normal functioning grafts showing 0.9 and 0.8 mg/dL serum creatinine levels at month 3 posttransplant. Close monitoring of recipients after transplant is mandatory for early diagnosis and early management of external iliac artery dissection to prevent graft loss and preserve lower limb circulation. Routine Doppler ultrasonography is an inexpensive and useful tool for early diagnosis in cases of sudden cessation or decrease in urine. In cases of failed percutaneous interventional angioplasty, reconstruction with synthetic vascular grafts can be safely applied in external iliac artery dissection.

Key words: *Interventional angioplasty, Kidney transplantation, Polytetrafluoroethylene graft*

From the [1]Department of General Surgery, Başkent University, Faculty of Medicine, Ankara, Turkey; the [2]Department of General Surgery , Başkent University, Faculty of Medicine, İstanbul, Turkey; and the [3]Department of Radiology, Başkent University, Faculty of Medicine, İstanbul, Turkey

Acknowledgements: *The authors have no sources of funding for this study and have no conflicts of interest to declare.*

Corresponding author: *Mehmet Haberal, Baskent University, Taskent Caddesi No:77, Bahcelievler, Ankara 06490, Turkey*

Phone: *+90 312 212 73 93* ***E-mail:*** *rectorate@baskent.edu.tr*

Experimental and Clinical Transplantation (2025) 2: 154-157

Copyright © Başkent University 2025
Printed in Turkey. All Rights Reserved.

DOI: 10.6002/ect.2016.0091

Introduction

Renal transplant (RT) is the only treatment option that can increase quality of life and the lifespan of patients with end-stage renal disease (ESRD). Success rates of RT have improved with advances in surgical techniques and immunosuppressive protocols. However, vascular complications, infections, and rejection are still major complications that negatively affect graft and patient survival.[1]

The overall incidence of vascular complications after RT is low. Arterial complications are more frequent and deadly than venous complications. External iliac artery dissection (EIAD) related to trauma due to vascular clamping is a rare complication and only reported in 6 cases in the literature.[1,2] However, treatment is urgently required due to its devastating effects on graft and lower limb circulation. External iliac artery dissection is seen more often in recipients with diabetes mellitus and other peripheral arterial diseases.[3] Between October 1985 and December 2015, we performed 2248 RT procedures at our centers with only 2 patients having EIAD complications. Here, we present the management of 2 cases with traumatic EIAD due to vascular clamping.

Case Report

Case 1

A 33-year-old male patient presented with ESRD of unknown cause for 3 months. He was preemptive and had no comorbid disease except hypertension. He underwent living-donor RT with donation from his father. Preoperative Doppler ultrasonographic imaging scans of the bilateral iliac arteries and veins were normal. The operative procedure involved a modified left Gibson incision, and iliac vessels were dissected. The left common iliac artery, external iliac artery, and internal iliac artery were normal. Renal

vein anastomosis was performed to the external iliac vein with 7/0 continuous polypropylene sutures using the 2-quadrant technique. The anastomosis was uneventful. After vascular clamping, the grafted kidney artery was anastomosed to the external iliac artery with 7/0 continuous polypropylene sutures using the 4-quadrant technique. After the vascular clamps were opened, the kidney tonus was normal. A thrill on the renal artery was present, and distal pulse of the external iliac artery was also normal. Urine excretion started in less than 1 minute.

At hour 3, due to sudden anuria, we performed a Doppler ultrasonography of the graft. The test showed no flow in the external iliac artery and low renal arterial flow. Immediate angiography was planned for diagnosis and treatment. Vascular access through the left femoral artery was impossible. Therefore, the angiography was done through the right femoral artery. Here, we found right EIAD. Dissection started just proximal to the anastomosis; however, renal artery flow was still continuing (Figure 1A).

Percutaneous stenting was not possible; therefore, urgent surgical reconstruction was planned. During exploration, we found renal blood flow to be low and observed the external iliac artery to be completely dissected distal to the renal artery anastomosis. The dissected external iliac artery segment was replaced with a 10-mm expanded polytetrafluoroethylene (ePTFE) vascular graft. A distal anastomosis was performed end-to-end between the ePTFE and the femoral artery using continuous 7/0 polypropylene sutures. A proximal anastomosis was also performed end-to-end between the ePTFE and common iliac artery using continuous 7/0 polypropylene sutures (Figure 1B-1D).

The renal artery anastomosis was disrupted, and the kidney was reperfused with tissue preservation solution. After this, the renal artery was anastomosed to the vascular graft using 7/0 continuous polypropylene sutures. Vascular clamps were opened again, and the entire graft was reperfused, which showed excellent graft tonus and renal artery thrill. Intraoperative Doppler ultrasonography scan was repeated, and graft perfusion and distal flow in the external iliac artery were within normal ranges. Urinary output started immediately during the early postoperative period. Clopidogrel at 75 mg and low-molecular-weight heparin were started. The patient was discharged on day 7 after the operation with normal serum creatine level of 1 mg/dL. At month 3, his serum creatine level was 0.9 mg/dL.

Figure 1. Case 1

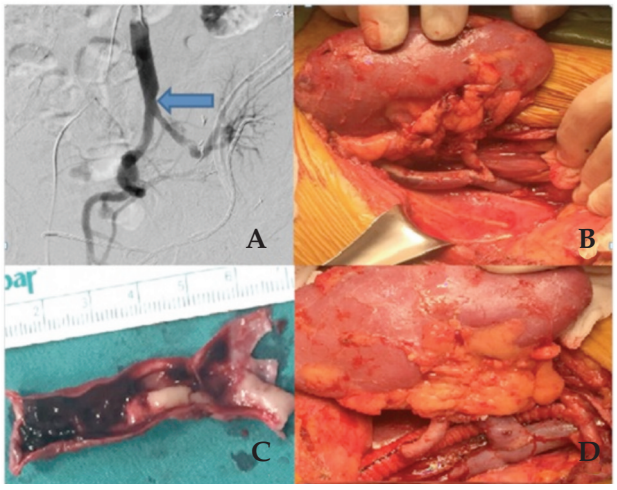

(A) External iliac artery dissection marked with arrow. **(B)** External iliac artery dissection. **(C)** Dissected eksternal iliac artery. **(D)** External iliac artery is replaced with expanded polytetrafluoroethylene graft. Images are 144 × 115 mm (96 × 96 dpi).

Case 2

A 55-year-old woman with chronic renal failure was evaluated for living related-donor kidney transplant. She had diabetes for 15 years and was on dialysis for 5 years due to diabetic nephropathy. She also had hypertension for 5 years and coronary artery disease with coronary artery stent replacement 2 years previously. Iliac artery and vein Doppler ultrasonography scans were normal on pretransplant evaluation.

The transplant procedure was started with a modified right Gibson incision, and the iliac vessels were dissected. It was noted that the common iliac artery, external iliac artery, and internal iliac artery had diffuse atherosclerosis. An uneventful renal vein anastomosis was performed to the external iliac vein with 7/0 continuous polypropylene sutures using the 2-quadrant technique. The graft kidney artery was anastomosed to the external iliac artery with 7/0 continuous polypropylene sutures using the 4-quadrant technique.

After the vascular clamps were opened, graft reperfusion started slowly with normal kidney tonus. There was no thrill on renal artery, and the distal pulse of the external iliac artery was weak. An emergent intraoperative Doppler ultrasonography scan was performed, which demonstrated no flow at the distal external iliac artery and insufficient kidney

reperfusion. Renal artery anastomosis was then disrupted, and the kidney was reperfused with tissue preservation solution. Examination of the external iliac artery showed a complete dissection from the beginning to almost the end of the external iliac artery. An external iliac artery segment was resected (12 cm length), and a ring 7.4-mm ePTFE vascular graft was used for replacement and anastomosed using 7/0 continuous polypropylene sutures from femoral artery to common iliac artery.

To perform renal artery anastomosis, 4 rings of the vascular graft were next removed, and the renal artery was anastomosed to the vascular graft using 7/0 continuous polypropylene sutures (Figure 2). Vascular clamps were opened again, and an entire graft reperfusion with excellent graft tonus and renal artery thrill was observed. Intraoperative Doppler ultrasonography scan was repeated, and graft perfusion and distal flow on the external iliac artery were within normal ranges. Subcutaneous low-molecular-weight heparin (enoxaparin sodium) at 40 mg/0.4 mL was started at twice per day after the operation, but it was discontinued because of a perirenal hematoma detected with Doppler ultrasonography scan and abdominal computed tomography scan on posttransplant day 1. The patient was reoperated, and the hematoma was drained.

Figure 1. Case 2

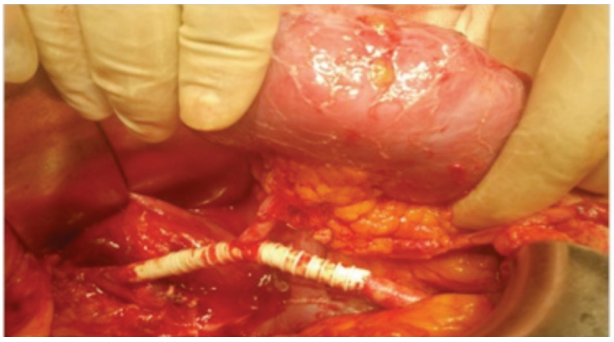

External iliac artery is replaced with expanded polytetrafluoroethylene. Image is 102 × 59 mm (96 × 96 dpi).

Clopidogrel at 75 mg and aspirin at 100 mg per day were started on posttransplant day 3. Antithymocyte globulin induction therapy was administered at the time of transplant as well for 5 days thereafter. Tacrolimus (target level 8-10 ng/mL), mycophenolate sodium (720 mg twice per day), and prednisolone were started as immunosuppressive therapies. Control Doppler ultrasonography scan was repeated on postoperative days 1 and 3. The patient was discharged on postoperative day 10 with a serum creatinine level of 1.35 mg/dL without complications.

Discussion

Traumatic EIAD is a rare but devastating complication after kidney transplant. External iliac artery dissection related to trauma due to vascular clamping is a rare complication and has been reported in only 6 cases in the literature.[1] Four EIADs were diagnosed after transplant, and 2 EIADs were seen intraoperatively. In our study, we diagnosed 1 intraoperative EIAD and 1 EIAD in the early postoperative period.

External iliac artery dissection after RT appears with hypertension, sudden pain in a lower limb without pulse, oliguria, or anuria. Graft artery and femoral artery blood flow cannot be visualized by Doppler ultrasonography.[1] In our case 2, intraoperative kidney perfusion was distorted and intraoperative Doppler ultrasonography could not visualize renal artery and external iliac artery blood flow. In case 1, EIAD was detected using Doppler ultrasonography that was performed after suspicion due to sudden anuria.

Vascular atherosclerosis and cardiomyopathy are predisposing factors for EIAD after RT.[4] In addition to senility, hypertension, dyslipidemia, smoking, and diabetes, many extraordinary risk factors (like anemia, microalbuminuria, and oxidative stress) may play a role in EIAD in patients with ESRD.[5] One of our patients had diabetes and hypertension for 15 years. Iliac artery and vein Doppler ultrasonography scans were normal in both patients without atherosclerosis.

In the literature, 4 cases were treated by percutaneous angioplasty and stenting, 1 case was treated with bypass surgery, and 1 case was managed with thrombectomy and angioplasty. We performed immediate reconstruction with ePTFE graft in our case 2 in which EIAD was diagnosed intraoperatively. In our other patient, reconstruction with ePTFE graft was done after failed percutaneous interventional angioplasty. In both patients, renal arteries were anastomosed to the ePTFE graft.

Most EIAD cases after RT are due to vascular clamping, but in 1 case EIAD was reported as spontaneous.[6] In both of our patients, EIADs were after vascular clamping. Vascular clamping should be done carefully.

In the literature, both plastic clamps and metallic clamps with plastic protector attachments may be used for kidney transplant. In our center, we use vascular clamps with plastic protector attachments for advanced atherosclerotic vessels. In the 2 patients described here, we did not use atherosclerotic sites of the vessels for clamping so we preferred metallic clamps. In addition, we believe that the main cause of dissection was due to rapid shutdown of the vessels.

In conclusion, EIAD is a rare but threatening complication for graft and patient survival. Close postoperative monitoring of urine excretion and routine ultrasonographic imaging are crucial for early diagnosis of EIAD. Early diagnosis and early treatment improve distorted graft and lower limb circulation. External iliac artery dissection can be safely reconstructed with synthetic vascular grafts in cases of failed percutaneous interventional angioplasty.

References

1. Chen CH, Chen CH, Hsieh SR, Shu KH, Ho HC. Salvage of external iliac artery dissection immediately after renal transplant. *Exp Clin Transplant.* 2013;11(3):274-277.
2. Kimura T, Saito T, Tsuchiya T, et al. Treatment of external iliac artery dissection with endovascular stent placement in a patient with simultaneous pancreas and kidney transplantation. *Transplant Proc.* 2005;37(8):3572-3573
3. Merkus JW, Dun GC, Reinaerts HH, Huysmans FT. Iliac artery dissection after renal transplantation. *Nephrol Dial Transplant.* 1992;7(12):1242-1245.
4. Shamseddin MK, Parfrey PS. Mechanisms of the cardiorenal syndromes. *Nat Rev Nephrol.* 2009;5(11):641-649.
5. Kendrick J, Chonchol MB. Nontraditional risk factors for cardiovascular disease in patients with chronic kidney disease. *Nat Clin Pract Nephrol.* 2008;4(12):672-681.
6. Esteban RJ, Sánchez D, González F, Bravo JA, Asensio C. Spontaneous iliac artery dissection in a kidney transplantation treated with and endovascular stent. *Nephrol Dial Transplant.* 1999;14(6):1610.